



Postmenopausal Vaginal Endometriotic Cyst: A Case Report

Postmenopozal Vajinal Endometriotik Kist: Bir Vaka Sunumu

Postmenopausal Vaginal Endometriotic Cyst

Esengul Turkyilmaz¹, Ayşegül Cinkaya¹, Elcin Islek Secen¹, Serra Kayacetin², A. Filiz Yavuz Avsar³

¹Department of Gynecology and Obstetrics, Ataturk Education and Research Hospital,

²Department of Pathology, Yildirim Beyazit University,

³Department of Gynecology and Obstetrics, Yildirim Beyazit University, Ankara, Turkey

Özet

73 yaşındaki hastanın jinekolojik muayenesi vajenin orta 1/3 bölümü, arka duvarında görülen yarı hareketli kistik yapıyı açığa çıkardı. Kist eksize edildi ve kist duvarı patolojik incelemeye gönderildi. Kistin CD 10 boyası ile histopatolojik muayenesi ve nükleer estrogen ve progesterone reseptör pozitifliği için yapılan testler kist duvarının endometrial stromal hücreler, endometrial yüzey epitelyal hücreler ve hemosiderin laden makrofajları içerdiğini gösterdi. Bu bulgularla endometriosis externa tanısı konuldu. Burada bildirilen izole vajinal endometriotik kist vakası infertilite öyküsü, herhangi bir jinekolojik cerrahi veya hormon replasman tedavisi öyküsünün olmamasıyla tektir. Bu vaka için olası açıklama premenopozal dönemde vajinaya implante olan endometriotik hücrelerin lokal östrojen üretimi ile kendi devamlılığını sağlamasını içeren belirli mekanizmalardır. Farklı form ve prezentasyonlardaki tüm endometriosis vakalarının patofizyolojisini tek bir teori açıklayamamaktadır.

Anahtar Kelimeler

Menopoz; Prostaglandin E; Endometriyoz

Abstract

A seventy-three-year-old patient's vaginal examination revealed a semi-mobile cystic structure visualised at the middle third portion of the posterior vaginal wall. The cyst was excised and the cyst wall was sent for pathological examination. The histopathological examination of the cyst with CD10 staining and tests for nuclear estrogen receptor positivity and nuclear progesterone receptor positivity revealed that the cyst wall contained endometrial stromal cells, endometrial surface epithelial cells, and hemosiderin-laden macrophages. Endometriosis externa was diagnosed based on the above findings. The case we report here, of an isolated vaginal endometriotic cyst, is unique because of its presentation in a postmenopausal woman without any history of infertility, any gynecologic surgery, or hormone replacement therapy. The reasonable explanation for this case might include certain mechanisms such as the self-sustaining existence of endometriotic cells that were implanted during the premenopausal period to the vagina and that maintain local estrogen production. No single hypothesis can explain the pathophysiology of endometriosis, given all of its various forms and presentations.

Keywords

Menopause; Prostaglandins E; Endometriosis

DOI: 10.4328/JCAM.4401

Received: 15.02.2016 Accepted: 14.03.2016 Printed: 01.07.2016

J Clin Anal Med 2016;7(4): 563-6

Corresponding Author: Esengul Turkyilmaz, Department of Gynecology and Obstetrics, Ataturk Education and Research Hospital, Ankara, Turkey.

GSM: +905053994864 E-Mail: turkyilmaz06@yahoo.com

Introduction

Endometriosis is a benign gynecological condition in which normal endometrial glands and stroma are localized outside of the uterus. The incidence of endometriosis among postmenopausal women is nearly 2.5% [1]. Although hormonal dependence therapy is considered a risk factor for postmenopausal endometriosis, there are an increasing number of reports of postmenopausal endometriosis cases without high systemic estrogen levels; this increase challenges our understanding of the pathophysiology of endometriosis.

Endometriosis may develop in any pelvic structure or on the peritoneal surfaces outside of the pelvis. Interestingly, the case of an isolated vaginal endometriotic cyst reported here is unique because of its presentation in a postmenopausal woman with no history of infertility, gynecologic surgery, previous vaginal trauma, or hormone replacement therapy.

Our aim is to report this case of postmenopausal endometriosis and to discuss the possible mechanisms underlying this disorder.

Case Report

A seventy-three-year-old woman, gravida 3, parity 3 was admitted to our outpatient clinic for a routine annual gynecological check-up. She was postmenopausal for the previous 22 years and had never received hormonal therapy. A vaginal examination revealed a semi-mobile cystic structure approximately 2x2 cm in diameter, arising from the middle third portion of the posterior vaginal wall. Transvaginal sonography showed an endometrial thickness of 8 mm and atrophic ovaries, normally located in the pelvis.

The patient was hospitalized before the surgical procedure. The cyst excision and endometrial sampling were planned accordingly. During the excision, the vaginal cyst ruptured, revealing a brown hemorrhagic content. The cyst wall was extirpated and sent for pathological investigation and endometrial sampling was carried out afterwards.

The histopathological examination showed normal endometrial tissue fragments with endometrial stromal cells and surface epithelial cells containing hemosiderin-laden macrophages. The cyst wall contained endometrial stroma confirmed with CD10 staining, nuclear estrogen receptor positivity, and nuclear progesterone receptor positivity. The diagnosis was made as endometriosis externa with endometrial stromal and surface epithelial cells containing hemosiderin-laden macrophages. We are unable to submit preoperative or intraoperative photographs of the lesion since we did not expect that the histopathological examination would indicate an endometriotic cyst.

Endometrial stromal and surface epithelial cells containing hemosiderin-laden macrophages are seen in Figure 1. CD10 staining of the cyst wall is seen in Figure 2. Nuclear estrogen positivity of the endometrial stroma is seen in Figure 3.

The patients had no history of any postmenopausal hormone replacement therapy, previous vaginal trauma, or surgical history. During her reproductive years, she had had neither any chronic pelvic pain nor any sign of an endometrioma. Her body mass index (BMI) was calculated as 26.

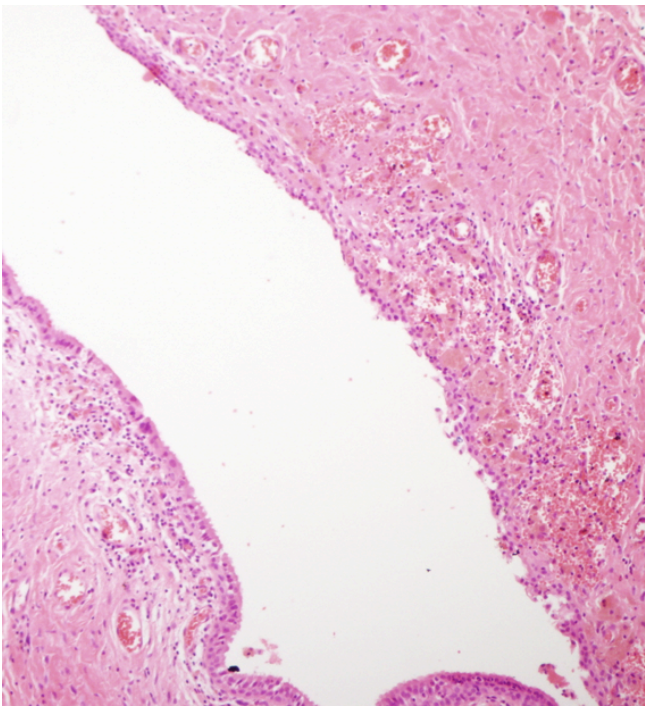


Figure 1. Endometrial stromal and surface epithelial cells containing hemosiderin-laden macrophages. (Hematoxylin-eosin staining X100)

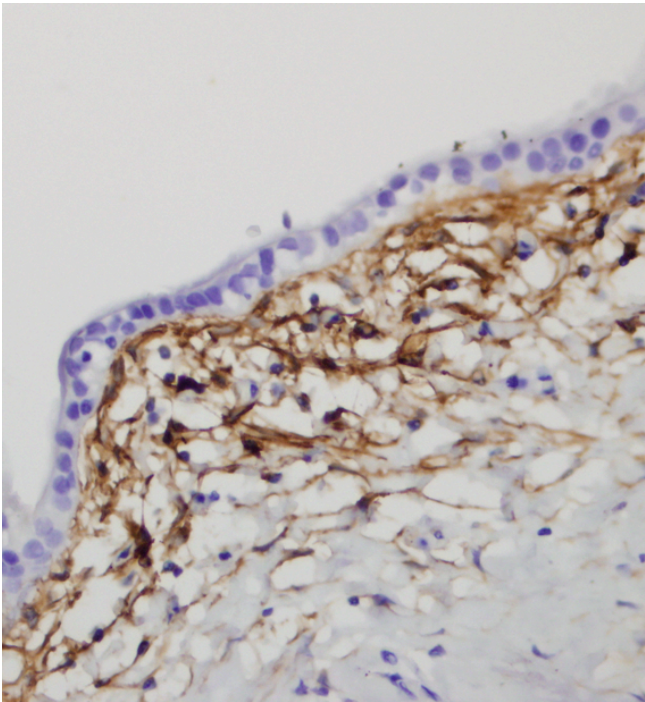


Figure 2. CD10 staining of the cyst wall (10X400)

Discussion

Endometriosis is a chronic disorder with an unclear pathophysiology. Although the presentation of the disease can vary among women of reproductive age, most of the cases resolve during the postmenopausal period due to the lesion's estrogen dependency. Several studies have demonstrated the relationship between postmenopausal endometriosis and the presence of high estrogen levels (iatrogenic or endogenous) in the body [2]. Based on all these studies, the presence of postmenopausal endometriosis can be explained by the hormonal dependence theory [3]. Receiving postmenopausal hormone replacement therapy (HRT) may lead to an increased risk of endometriosis

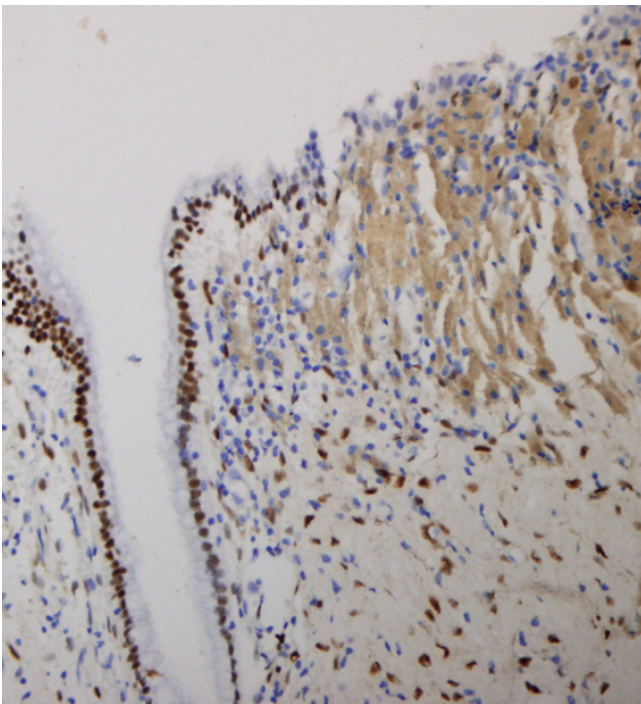


Figure 3. Nuclear estrogen positivity of the endometrial stroma (CD 10 staining X200)

recurrence or occurrence of de novo lesions [2]. Ovarian estrogen secreting tumors can be one additional cause of postmenopausal endometriosis. These tumors can be imaged by vaginal sonography, magnetic resonance imaging, or computerized tomography of the pelvis, although smaller tumors can only be detected by laparoscopy. No ovarian tumor was detected by the pelvic sonography of our patient. During the postmenopausal period, adipose tissue provides the largest part of the estrogen. Because of the estrogen production, obesity becomes a possible risk factor for postmenopausal endometriosis. Even though estrogen is considered a primary etiologic factor for the development of endometriosis, lesions identified in postmenopausal women with no history of HRT use and without an estrogen-producing source cannot be explained by the same mechanism.

Some postmenopausal endometriosis cases can be explained either by a probable mechanism of coelomic metaplasia [4] or induction theory which proposes that some biological and hormonal factors induce undifferentiated cells to differentiate into endometrial cells [5]. Moreover, some of the postmenopausal endometriosis cases can occur due to immunosuppression that alters the appearance of the endometriosis or causes the progression of the lesion [6]. Furthermore, a number of studies have shown that increased local activity of P450 aromatase and IL-6 and TNF- α levels in the endometriotic lesions lead to the local synthesis of estrogen and cause the exacerbation of symptoms without having any other hormonal source in the body [4]. It is also shown that stromal cells cultured from endometriotic lesions express each of the prostaglandin E2 receptor subtypes, namely EP1, EP2, EP3, and EP4. Activation of the EP2 receptor raises the intracellular levels of cyclic AMP (cAMP), which is responsible for inducing the expression of STAR and CYP19A1 via prostaglandin E2 in endometriotic stromal cells. PGE2 increases steroidogenic acute regulatory protein (STAR) and aromatase levels and activity in endometriotic cells, but

not in endometrial stromal cells. Thus, local hyper-estrogenism stimulates the growth and implantation of endometriotic lesions [7,8]. This theory explains the endometriosis as a lesion with self-sustaining existence and can be helpful in explaining endometriotic lesions described in the postmenopausal women whose circulating estrogen levels are not as high as those in younger subjects.

In this case report, the hormonal dependence theory was insufficient to explain endometriosis since the patient neither demonstrated any signs of an estrogen-producing source such as adrenal or ovarian tumors, nor she was receiving HRT. Obesity is considered a possible risk factor for the development of postmenopausal endometriosis. However, our patient did not have any form of obesity as her BMI was only 26 kg/m². Since the patient had no symptoms suggesting endometriosis during the preoperative period, serum estrogen levels were not measured and remained unknown, but postoperative estrogen levels were normal at the first month after the operation. The patient was also not immunosuppressed at the time of the diagnosis.

Although a case study reported that endometriosis was identified in postmenopausal women with a history of hormone replacement therapy, pelvic endometriosis, and infertility [9], our report is unique with regard to describing a postmenopausal case of an isolated vaginal endometrioma without having any of the aforementioned risk factors. While most postmenopausal endometriosis cases are identified in the ovaries, the present study is the first in the literature that demonstrates a postmenopausal vaginal endometriotic cyst. This presentation made us consider that different pathophysiological mechanisms may be operational in the genesis of endometriosis. The reasonable explanation for this case may involve some mechanisms such as self-sustaining existence that maintains the local estrogen production from endometriotic cells which were implanted into the vagina during the premenopausal period and transformed via coelomic metaplasia. Another possible mechanism may be the transportation of endometrial stem cells from vascular endometrial cells, which occurs primarily when endometriotic lesions appear in areas that do not have contact with menstrual retrograde flow [10].

Among different theories, there is no single hypothesis of the pathophysiology of postmenopausal endometriosis, which has diverse forms and presentations. Therefore, endometriosis should come to mind whenever a cyst is detected at atypical localizations in a postmenopausal woman.

Competing interests

The authors declare that they have no competing interests.

References

1. Haas D, Chvatal R, Reichert B, Renner S, Shebl O, Binder H, et al. Endometriosis: a premenopausal disease? Age pattern in 42,079 patients with endometriosis. *Arch Gynecol Obstet* 2012;286(3):667-70.
2. Oxholm D, Knudsen UB, Kryger-Baggesen N, Ravn P. Postmenopausal endometriosis. *Acta Obstet Gynecol Scand* 2007;86(10):1158-64.
3. Gurates B, Bulun SE. Endometriosis: the ultimate hormonal disease. *Semin Reprod Med* 2003;21(2):125.
4. John O. Schorge, Joseph I. Schaffer, Lisa M. Halvarson, Barbara L. Hoffman, Karen D. Bradshaw, F. Gary Cunningham, editors. *Williams Gynecology*, Parkland Health and Hospital System. Texas: Dallas; 2008. p.226.
5. Bontis JN, Vavilis DT. Etiopathology of endometriosis. *Ann N Y Acad Sci* 1997;816:305.
6. González Ramos P, Manero P, Pastor OC, Calleja Aguayo E, De Martino A, Rodi-

no J, et al. GREMIO Collaboration Group. University of Zaragoza (Spain). PGR-1 Hot-Dog: a new rat model for the study of the experimentally-induced endometriosis in rats. Proceedings of the 13th World Congress on Human Reproduction: Venice (Italy) 2009;89:161.

7. Noble LS, Takayama K, Zeitoun KM, Johns DA, Hinshelwood MM, Agarwal VR, et al. Prostaglandin E2 stimulates aromatase expression in endometriosis-derived stromal cells. The Journal of Clinical Endocrinology and Metabolism 1997;82(2):600–6.

8. Sun HS, Hsiao KY, Hsu CC, Wu MH, Tsai SJ. Transactivation of steroidogenic acute regulatory protein in human endometriotic stromal cells is mediated by the prostaglandin EP2 receptor. Endocrinology 2003;144(9):3934–42.

9. Rosa-e-Silva JC, Carvalho BR, Barbosa Hde F, Poli-Neto OB, Rosa-e-Silva AC, Candido-dos-Reis FJ, et al. Endometriosis in postmenopausal women without previous hormonal therapy: report of three cases. Climacteric 2008;11(6):525-8.

10. Jelovsek JE, Brainard J, Winans C, Falcone T. Endometriosis of the liver. Am J Obstet Gynecol 2004; 191(5):1725–77.

How to cite this article:

Turkyılmaz E, Cinkaya A, Secen EI, Kayacetin S, Yavuz Avsar AF. Postmenopausal Vaginal Endometriotic Cyst: A Case Report. J Clin Anal Med 2016;7(4): 563-6.